

The Journal of

# Clinical *and* Aesthetic Dermatology

A PEER-REVIEWED JOURNAL PROVIDING EVIDENCE-BASED INFORMATION TO PRACTICING CLINICIANS

VOL. 5, NO. 10 • OCTOBER 2012

## Lipodissolve for Body Sculpting

### *Safety, Effectiveness, and Patient Satisfaction*

Efficacy and Safety of a Low-Molecular Weight Hyaluronic Acid  
Topical Gel in the Treatment of Facial Seborrheic Dermatitis

Osteopathic Manipulative Treatment  
*Novel Application to Dermatological Disease*

Invasive Ductal Breast Carcinoma  
Underneath a Lipoma in a Male Patient

Lymphocytic Thrombophilic Arteritis  
Induced by Minocycline

Sister Mary Joseph Nodule as a Presenting Sign  
of Pancreatobiliary Adenocarcinoma

Acute Painful Nodules in a Young Healthy Adult



Scan this QR code  
with your QR reader  
for the digital edition  
of JCAD.

Now available on  
**PubMed Central!**

Presented Standard  
U.S. Postage  
PAID  
Lebanon Junction, KY  
Permit #344

# Lipodissolve for Body Sculpting

## Safety, Effectiveness, and Patient Satisfaction

<sup>a</sup>KHALID MAHMUD, MD, FACP; <sup>b</sup>CHARLES E. CRUTCHFIELD III, MD

<sup>a</sup>Innovative Directions in Health, Edina Minnesota; <sup>b</sup>University of Minnesota, Minneapolis, Minnesota; Crutchfield Dermatology, Eagan, Minnesota

---

### ABSTRACT

Lipodissolve, to reduce superficial deposits of fat, has gained popularity in recent years. A simple solution of phosphatidylcholine in deoxycholate evolved around 2004 and has been used by two collaborating physicians in Minnesota. Their experience encompassing 1,616 patients receiving a total of 15,122 treatments is described. Relatively modest volumes of injections produced satisfactory and smooth results in 74.5 to 86.5 percent of the patients in the two practices. No serious complications developed. Minor and rare side effects included pain, lightheadedness, tender nodules, pigmentation, and ulceration in two patients. The authors offer useful tips to enhance safety, effectiveness, and patient satisfaction with the procedure. (*J Clin Aesthet Dermatol.* 2012;5(10):16–19.)

---

Localized injections of phosphatidylcholine (PC) with deoxycholate (DC) to reduce superficial deposits of fat have gained popularity in the United States since the turn of the century. Initially, different practitioners added multiple other ingredients, including L-carnitine, aminophylline, collagenase, various vasodilators, and hyaluronidase. A standard formula with PC and DC as essential ingredients was then introduced in Europe and adopted by the American Society of Aesthetic LipoDissolve (ASAL) in the United States around 2004. Since then, several hundred physicians in the United States have treated thousands of patients.

The mechanism of action of the mixture is similar to that of bile, wherein DC (a bile salt) breaks down the ingested fat cells, and PC assists the digestion and drainage of released fat,<sup>1</sup> but mostly protects the neighboring mucosa from the corrosive action of DC.<sup>2-4</sup> It has been shown that when injected in subcutaneous fat, DC alone leads to adipocyte death<sup>5</sup>; however, there is less pain, bruising, and induration when combined with PC.<sup>6</sup> Once the fat cells are destroyed, they are slowly removed by the macrophages (foam cells) in the concomitant inflammatory response,<sup>7</sup> resulting in fat reduction in the treated area, while at the same time newly laid down collagen tightens the overlying skin. The techniques, efficacy, and side effects of lipodissolve have been the subject of several reports over the past five years.<sup>8-10</sup>

The following is a report of 1,616 patients who received 15,122 treatments of lipodissolve during the last 6 to 7 years by two Minnesota physicians who were a part of the ASAL. The results are described herein, followed by useful tips to enhance safety, efficacy, and patient satisfaction.

### AREAS TREATED

Abdomen, flanks, outer thighs (saddle bags), posterior upper thighs (banana roll), and anterior thighs (mostly cellulite) were the most common areas treated. Back, arms, and chin/jowls were less common.

### METHODS

The areas were marked by palpating exact outlines. For example, the abdomen was not injected as a whole, but as separate areas over the upper, lower, or periumbilical abdomen, which were marked exactly. Saddle bags were marked according to exact shape and extended to banana rolls, if necessary. Icing the area for 4 to 5 minutes seemed to reduce immediate stinging and pain and was used for most of the patients at one clinic. PC/DC injections were placed 1.5cm apart and at a depth of the middle of the fat pad and slightly more superficially in cases of cellulite to provide better skin tightening. The volume of the solution (PC 25mg/mL, DC 21mg/mL) varied from 20 to 30cc per flank or saddle bag to 40 to 60cc per abdominal area in the two different practices. A few double chins were treated

---

**DISCLOSURE:** The authors report no relevant conflicts of interest.

**ADDRESS CORRESPONDENCE TO:** Khalid Mahmud, MD, FACP, Innovative Directions in Health, 4005 West 65th Street, Suite 212, Edina, MN 55435; E-mail: kmahmud@idinhealth.com

**TABLE 1. Cumulative results**

RESULTS	PRACTICE A [60mL AVERAGE/Rx]	PRACTICE B [40mL AVERAGE/Rx]
Treatments per area	3	4
Patient satisfaction	86.6%	74.4%
Significant pain for up to three days leading to discontinuation	1.4%	1%
Significant dizziness leading to discontinuation	2.1%	1.5%
Residual pigmentation	1.4%	1.3%
Tender nodules lasting more than two months	1.6%	1.1%
Ulceration	0.39% (2 patients) <sup>a</sup>	None
Hives	0.39% (2 patients) <sup>b</sup>	None

<sup>a</sup>One patient had a previous diagnosis of Lupus (not disclosed to the authors) and received 40cc of the solution to each saddle bag. The other with upper inner thigh injections (30cc each side) had been walking with rubbing of the injected areas.

<sup>b</sup>Both of these patients had undisclosed soy allergy (usual PC/DC solution is soy based).

with 3 to 6cc. Ultrasound, for a few minutes, was added before or after injections for the possibility of improved adipocyte lysis.<sup>11,12</sup>

## RESULTS

All patients had some stinging and pain during, and for 30 minutes after, the procedure, which was reduced among the patients who received 4 to 5 minutes of icing before the procedure. A variable amount of swelling and bruising developed in almost all patients, but mostly subsided within 10 days. The overall results differed somewhat depending upon the volume of solution with each treatment (Table 1).

Practice A, using higher injection volume per treatment needed fewer treatments, 3 versus 4 per area, than practice B. The satisfaction rate was slightly better among those receiving higher injection volume, 86.6 percent in practice A versus 74.4 percent in practice B. When separated for body sculpting and cellulite, in practice B, the satisfaction rates were 81 and 44 percent, respectively. When response could be easily measured, such as abdominal circumference reduction in 95 patients, it varied from 0.125 to 3 inches per treatment, with an average of 1.1 inch. The fat reduction was generally associated with some degree of skin tightening, resulting in a smooth appearance. No patient developed lumpy, bumpy, or uneven appearance, as seen in some patients after liposuction. Complications were minor and extremely rare and developed in 1 to 2 percent of the patients (Table 1). Lightheadedness from hyperventilation, pain, and prolonged tender nodules were slightly more common in patients receiving a higher volume of injections (practice A). Complications of liposuction, such as pulmonary embolism, hemorrhage, perforation, lidocaine/

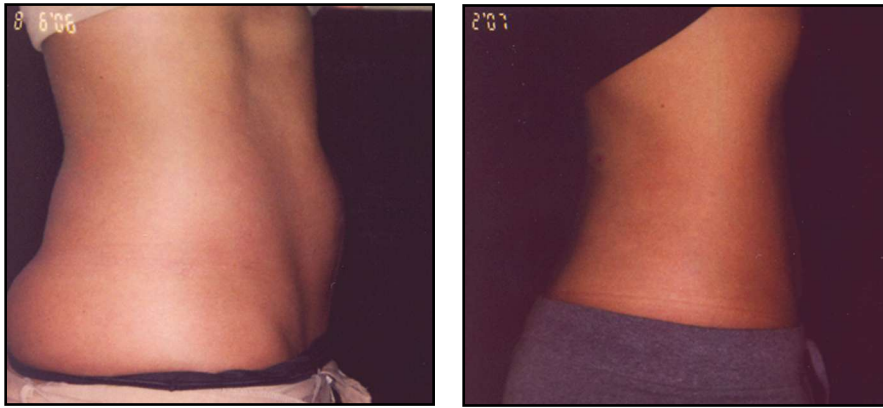
epinephrine toxicity, third space fluid shifts, and fat embolism,<sup>13,14</sup> did not occur with lipodissolve.

## DISCUSSION

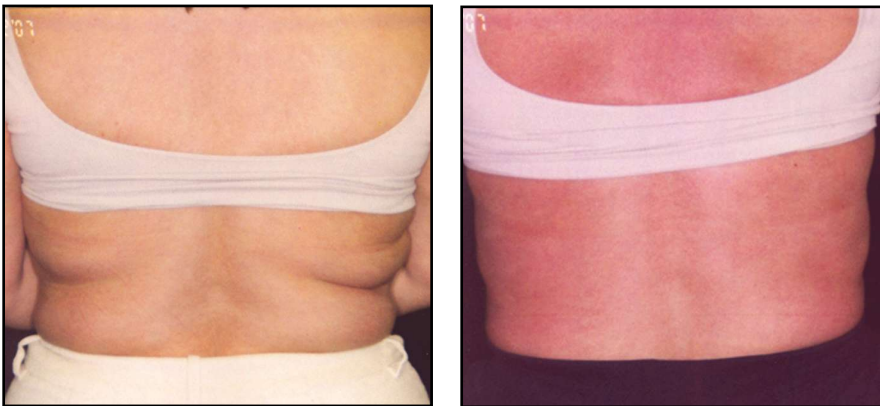These results, in conformity to others reported in the literature (cited above), reveal that lipodissolve is a highly effective procedure in reducing unwanted deposits of localized fat and that it can tighten the skin to some extent, providing smooth cosmetic results (Figures 1–4).

This is an observational report, not a prospective study, so institutional review board approval was not indicated. Because different areas of the body would show different amounts of shrinkage (e.g., abdomen vs. arm) and because the amount of fat being treated is highly variable in different individuals, the authors felt that they could not attach significance to circumferential reduction in centimeters to the entire group, but they have listed the measured reduction in 100 treated patients. In evaluating abdominal circumference reduction, the authors did see a statistically significant diminution (see Table 2). The most important parameter to the authors for this report was patient satisfaction with the procedure. The procedure should be preferred over liposuction for small-to-moderate areas of superficial fat to avoid possible complications of liposuction. Fat embolism, one of the complications of liposuction, has never been reported with lipodissolve. To the contrary, phosphatidylcholine has been used to treat fat embolism, such as with bone fractures.<sup>15</sup> There has been some conjecture and/or fear that lipodissolve may increase cholesterol. However, phosphatidylcholine has been shown to improve lipids and reduce cardiovascular risk factors.<sup>16–18</sup>

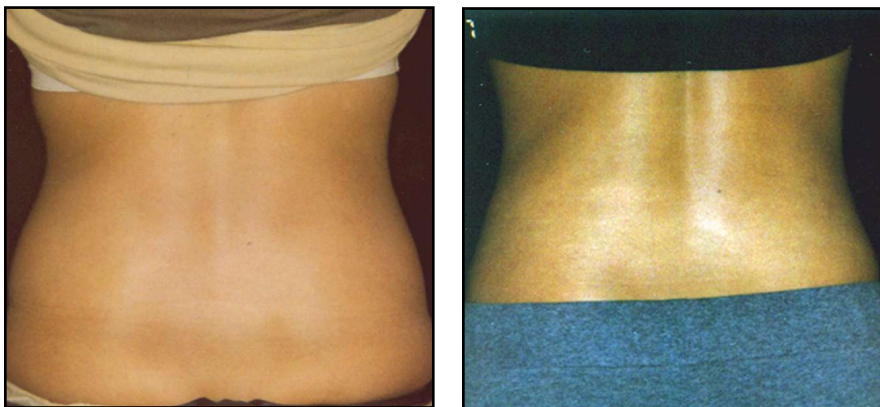
Large volumes of PC/DC injections, 100cc per area as



**Figure 1.** Abdominal treatments, before and after (4 treatments)



**Figure 2.** Bra/back fat treatments, before and after (4 treatments)



**Figure 3.** Flank treatments, before and after (4 treatments)

suggested a few years ago, do not seem to be necessary. A high degree of patient satisfaction can be achieved with as little as 40 to 60cc per treatment. More treatments may be needed with lower volumes, but as the authors' experience reveals, these treatments are better tolerated and with a lesser chance of complications.

Based on personal experience and review of the literature, the authors offer the following tips to enhance safety, effectiveness, and patient satisfaction with the procedure.

### SAFETY

- Avoid pregnant patients and patients with any systemic disease, such as heart disease, kidney disease, uncontrolled diabetes or hypothyroidism, infections, active or previous autoimmune disease, or active skin disorders.
- Avoid patients on aspirin or other anti-inflammatory drugs and those with a known bleeding tendency.
- Avoid patients with soy allergy (the usual PC/DC mixture is soy based).
- Avoid injecting breast or axillary tail of the breast. Prolonged inflammation could possibly stimulate malignant cells.
- Avoid injecting around the knees (too close to ligaments) and below the knee, as these areas may be more prone to skin breakdown.
- Inject the minimum volume necessary depending upon the area and amount of fat, usually 40 to 60cc.
- Injections should be 1.5cm apart and in the middle of the fat pad. Avoid injecting too close to the skin or underlying muscle and fascia.
- Avoid rubbing the area or wearing garments that are too tight.

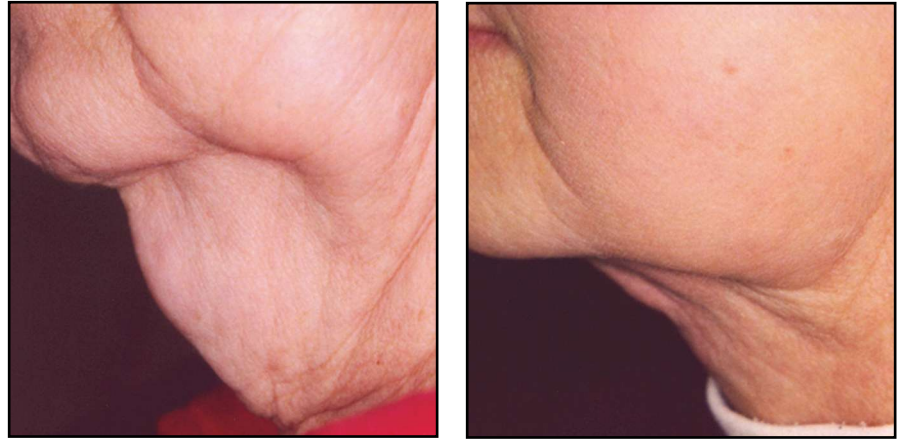TABLE 2. Reduction in inches			
MEANS WITH THE SAME LETTER ARE NOT SIGNIFICANTLY DIFFERENT			
DUNCAN GROUPING	MEAN	N	NUMBER OF TREATMENTS
A	2.9375	8	3
B	1.8214	21	2
C	1.1483	59	1



- Patient should avoid putting on lotions immediately after treatment to avoid infection. Wait for a few days until puncture sites have healed.

## EFFECTIVENESS

- Select patients with relatively localized areas of soft fat. Firm and fibrous fat tends not to respond as well.
- In patients with cellulite or skin laxity, inject somewhat more superficially, but still at a depth of 5mm, at least. Avoid patients with excessive skin laxity with minimal underlying fat.
- Palpate and mark the areas to be treated exactly. For example, some patients have a contiguous fat pad around the umbilicus, others have a large area below the umbilicus or both below and above the umbilicus, and others have multiple areas over the abdomen.
- Ultrasound immediately before or after the procedure may help fat cell lysis.
- Wait for 6 to 8 weeks before re-injecting the same area to have full effect of the first treatment.



**Figure 4.** Under chin treatments, before and after (4 treatments)

## PATIENT SATISFACTION

- Avoid patients with undue expectations, such as obese or overweight patients who feel this may lead to weight loss and really thin patients who imagine they have extra fat.
- Go over informed consent and the possibility of even rare complications. Inform them that there is a possibility of prolonged palpable nodules and pigmentation in a small number of patients, and pain that may last for three or more days.
- Inform the patient that it may take 3 to 4 treatments per area to have the desired effect. However, if there is absolutely no effect six weeks after the first treatment, it is helpful to have a frank discussion with the patient and better to avoid further treatment if the patient is skeptical.

## REFERENCES

1. Tso P, Kendrick H, Balint JA, et al. Role of biliary phosphatidylcholine in the absorption and transport of dietary triolein in the rat. *Gastroenterology*. 1981;80(1):60–65.
2. Tsuboi K, Tazuma S, Nshioka T, et al. Partial characterization of cytoprotective mechanisms of lecithin against bile salt-induced bile duct damage. *J Gastroenterol*. 2004;39(10):955–960.
3. Barrios JM, Lichtenberger LM. Role of biliary phosphatidylcholine in bile acid protection and NSAID injury of the ileal mucosa in rats. *Gastroenterology*. 2000;118(6):1179–1186.
4. Eros G, Kaszaki L, Czobel M, et al. Effects phosphatidylcholine pretreatment during acute experimental biliary reflux. *Magy Seb*. 2005;58(6):406–414.
5. Rotunda AM, Suzuki H, Moy RT, et al. Detergent effects of sodium deoxycholate are a major feature of an injectable phosphatidylcholine formulation used for localized fat dissolution. *Dermatol Surg*. 2004;30(7):1001–1008.
6. Salti G, Ghersetich I, Tantussi F, et al. Phosphatidylcholine and sodium deoxycholate in the treatment of localized fat: a double-blind, randomized study. *Dermatol Surg*. 2008;34(1):60–66.
7. Rose PT, Morgan M. Histological changes associated with mesotherapy for fat dissolution. *J Cosmet Laser Ther*. 2005;7(1):17–19.
8. Palmer M, Curran J, Bowler P. Clinical experience and safety using phosphatidylcholine injections for the localized reduction of subcutaneous fat: a multicentre, retrospective UK study. *J Cosmetic Derm*. 2006;5:218–226.
9. Duncan DI, Chubaty R. Clinical safety data and standards of practice for injection lipolysis: a retrospective study. *Aesthetic Surg J*. 2006;26(5):1–12.
10. Duncan DI, Palmer M. Fat reduction using phosphatidylcholine/sodium deoxycholate injections: standard of practice. *Aesth Plast Surg*. 2008;32:858–872.
11. Silberg BN. The technique of external ultrasound-assisted lipoplasty. *Plast Reconstr Surg*. 1998;101:552.
12. Hoefflin SM. Lipoplasty with hypotonic pharmacologic lipo-dissolution. *Aesth Surg J*. 2002;22:573–576.
13. Toledo LS, Mauad R. Complications of body sculpture: prevention and treatment. *Clin Plast Surg*. 2006;33(1):1–11, V.
14. Platt MS, Kohler LJ, Ruiz R, et al. Deaths associated with liposuction: case reports and review of the literature. *J Forensic Sci*. 2002;47(1):205–207.
15. Masella L, Viscdi E, Buffardini G, et al. Polyunsaturated phosphatidylcholine in pulmonary fatty microembolism in patients with multiple fractures. *Clin Ter*. 1983;105(1):13–22.
16. Klimov AN, Konstantinov VO, Lipovestsky BM, et al. Essential phospholipids versus nicotinic acid in the treatment of type 2 hyperlipoproteinemia and ischemic heart disease. *Cardiovasc Drugs Ther*. 1995;9(6):779–784.
17. Jimenez MA, Scarino ML, Vignolini F. Evidence that polyunsaturated lecithin induces a reduction in plasma cholesterol and favorable changes in lipoprotein composition. *J Nutr*. 1990;120(7):659–667.
18. Lombard E, Marin V, Domingo N, et al. Anionic peptide factor/phosphatidylcholine particles promote the inhibition of vascular cell adhesion molecule-1 in human umbilical vein endothelial cells. *Pathobiology*. 2005;72(4):213–219. ●